

Virus-like Drug Conjugates (VDC), a paradigm shifting approach for the treatment of bladder cancer

Mechanism, First Insights, and Future Directions

*P. Black, Vancouver (CA), L. Bukavina, Philadelphia (US), S. Shariat, Vienna (AT)
S. D. Brookman-May, Aura Biosciences Boston (US), University of Munich, LMU, Munich (DE)*

EAU25
MADRID, SPAIN
21-24 March 2025

Cutting-edge Science at
Europe's largest Urology Congress



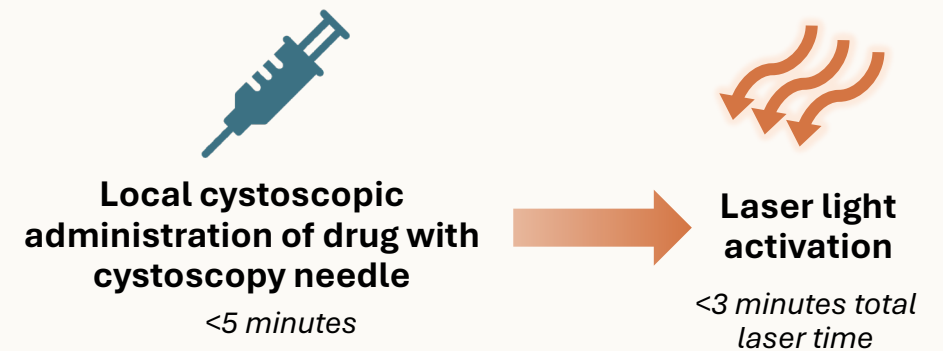
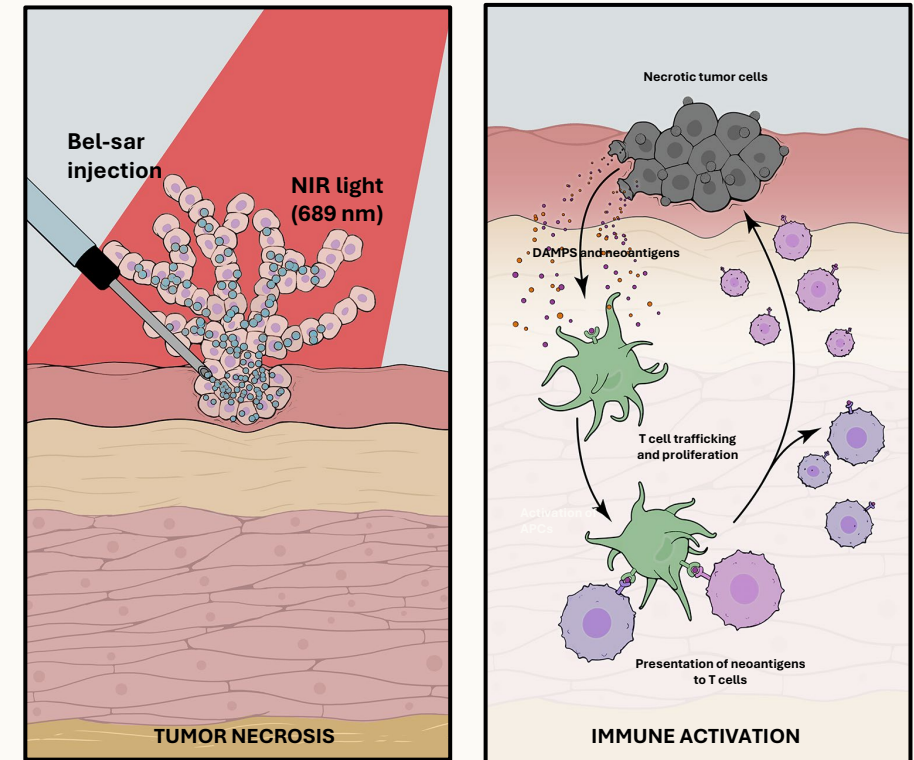
Investigational Product Candidates

This presentation discusses product candidates that are under preclinical or clinical evaluation and that have not yet been approved for marketing by the U.S. Food and Drug Administration (FDA) or any other regulatory authority. Until finalized in a clinical study report, clinical trial data presented herein remain subject to adjustment as a result of clinical site audits and other review processes. No representation is made as to the safety or effectiveness of these product candidates for the use for which such product candidates are being studied

Conflict of Interest Disclosures: SBM: Aura Biosciences, Boston (US). **PB: Consultant:** AbbVie, Astellas, AstraZeneca, Aura, Bayer, BMS, CG Oncology, Combat, EMD-Serono, Ferring, J&J, Merck, Nonagen, Nanobot, NanOlogy, Photocure, Prokarium, Sumitomo, TerSera, Tolmar, Verity; **Speaker:** Bayer, TerSera; **Clinical Trials:** Sustained Therapeutics, CG Oncology, J&J; **Patent:** Veracyte. **No conflicts reported by SS and LB**

Background – AU-011 (Bel-sar)

- Current standard of care for NMIBC leaves a large, unmet medical need:
 - High recurrence rates
 - Need for repeat surgeries and adjuvant treatments
- AU-011 is a focally administered, Virus-like-Drug-Conjugate (VDC) with an **immune-ablative dual mechanism of action**:
 - Selective binding to tumor-expressed heparan sulfate proteoglycans (HSPG)
 - Induction of immediate tumor necrosis after light activation
 - Stimulation of anti-tumor immunity
- AU-011 demonstrated 80% tumor control rate at 12 months in a Phase 2 trial in early-stage choroidal melanoma*



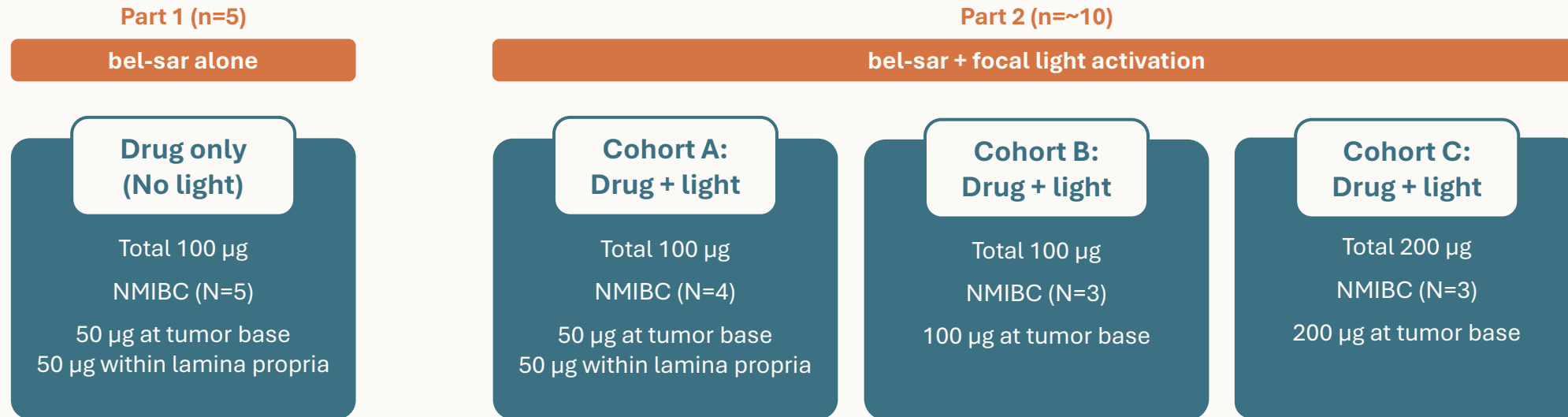
Kines RC, et al. *Int J Cancer*. 2016;138(4):901–11. Kines RC, et al. *Mol Cancer Ther*. 2018;17(2):565–74. Kines RC, et al. *Cancer Immunol Res*. 2021;9:693–706.

*Press release announcing Phase 2 end of study results available here: <https://ir.aurabiosciences.com/news-releases/news-release-details/aura-biosciences-reports-positive-phase-2-end-study-results>

Phase 1 trial of bel-sar for bladder cancer designed to evaluate safety, feasibility, and mechanism of action

Single dose window of opportunity study in NMIBC all-comers

Histopathological assessment completed at time of standard of care TURBT



Safety Review Board completed after each cohort. Patients followed for safety after TURBT to 56 days.

Study objectives

Safety & dose-limiting toxicity

Feasibility of technique

Focal distribution of bel-sar

Focal necrosis

Markers of immune activation

Efficacy data: Ta Intermediate-Risk NMIBC

4/5 patients demonstrated CR; 5/5 patients with immune response in target tumor

	Patient A1	Patient A3	Patient A4 ^c	Patient B2	Patient C1 ^d
Screening diagnosis	Multiple (TURBT) Ta low-grade	Multiple Ta low-grade	Multiple Ta low-grade Prior Ta high-grade	Multiple Ta low-grade	Multiple Ta low-grade
Screening AUA risk classification	Intermediate (TURBT)^f	Intermediate	Intermediate	Intermediate	Intermediate
AU-011 dose/delivery	100 µg IT/IM	100 µg IT/IM	100 µg IT/IM	100 µg IT	200 µg IT
Clinical complete response: Target tumor^a	✓	✓	✓	-	✓
Clinical complete response: Non-target tumor^a (bladder urothelial field effect^b)	2/2	1/2	1/1	0/1	0/1
Immune response^e: Target tumor	✓	✓	✓	✓	✓
Immune response^e: Non-target tumor	✓	✓	✓	✓	✓
Necrosis	✓	✓	✓	-	-
Visual changes on cystoscopy	✓	✓	-	Tumor Visually Smaller	✓

^aFor purposes of this analysis, Clinical complete response defined as absence of tumor cells on histopathologic evaluation. ^bBladder urothelial field effect: absence of tumor cells in non-target lesions. ^cPreviously treated tumor demonstrated high-grade disease but pathology at time of treatment revealed low-grade disease in non-target tumor. ^dLocal pathology with no evidence of carcinoma in 3/3 target specimens. Central pathology demonstrated single fibrovascular core in 1/3 target specimens consistent with small area of papillary disease of unclear distance from target injection. ^eImmune response is defined by immunocyte infiltration on post-treatment histopathology. ^fSingle lesion visualized at screening on office cystoscopy. Multiple lesions subsequently seen with improved visualization at time of TURBT qualifying for intermediate risk classification. AUA, American Urological Association; IM, intramural; IT, intratumoral; TURBT, transurethral resection of bladder tumor; CR, clinical complete response; NMIBC, non-muscle-invasive bladder cancer. Clinicaltrials.gov identifier: NCT05483868; AU-011-102.

Cohorts A-C:
Single-dose drug with light activation

Efficacy data: Ta High-Risk NMIBC

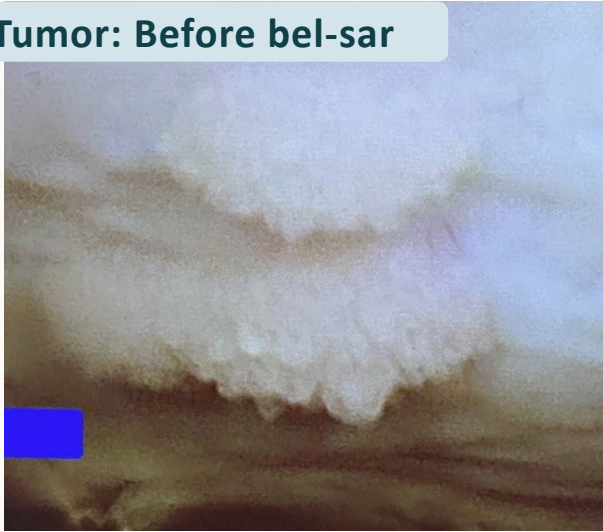1/5 patients demonstrated CR; 5/5 patients with immune response in target tumor

	Patient A2	Patient B1	Patient B3	Patient C2	Patient C3 ^d
Screening diagnosis	Single Ta high-grade	Multiple Ta high-grade	Single Ta high-grade	Multiple Ta high-grade	Multiple Ta low-grade Prior Ta high-grade
Screening AUA risk classification	High	High	High	High	High (BCG Failure)
AU-011 dose/ delivery	100 µg IT/IM	100 µg IT	100 µg IT	200 µg IT	200 µg IT
Clinical complete response: Target tumor^a	-	-	-	-	✓
Clinical complete response: Non-target tumor^a (bladder urothelial field effect^b)	NA	0/1	NA	NA	1/3
Immune response^c: Target tumor	✓	✓	✓	✓	✓
Immune response^c: Non-target tumor	NA	✓	NA	NA	✓
Necrosis	-	-	-	-	✓
Visual changes on cystoscopy	Tumor Visually Smaller	Tumor Visually Smaller	-	Tumor Visually Smaller	✓

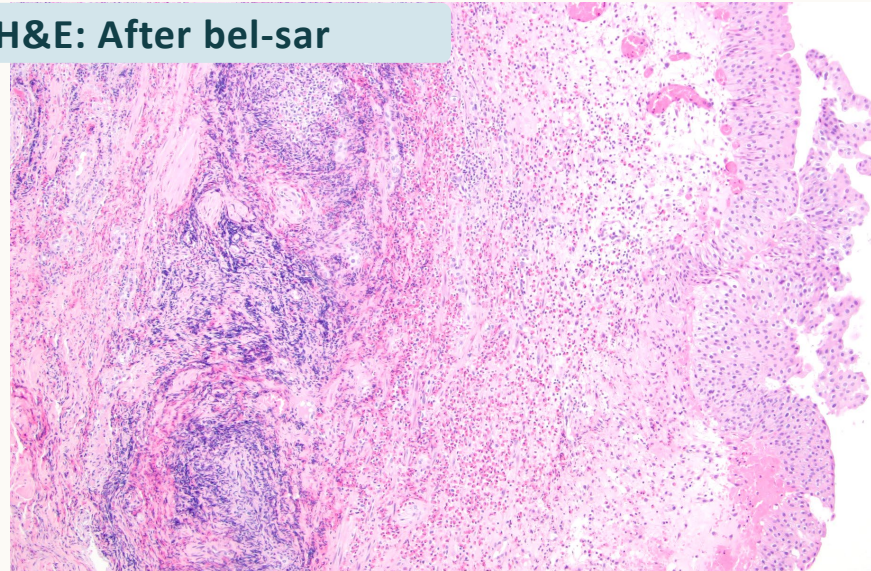
^aClinical complete response defined as absence of tumor cells on histopathologic evaluation. ^bBladder urothelial field effect: absence of tumor cells in non-target lesions. ^cImmune response is defined by immunocyte infiltration on post-treatment histopathology. ^dTwo tumors in target tumor field with 1/2 tumors with clinical complete response. BCG failure qualifying as high risk by AUA criteria. **AUA**, American Urological Association; **BCG**, Bacillus Calmette-Guerin; **IM**, intramural; **IT**, intratumoral; **CR**, clinical complete response. Clinicaltrials.gov identifier: NCT05483868; AU-011-102.

Visual and Immune Response in Patient A3: Intermediate-Risk NMIBC

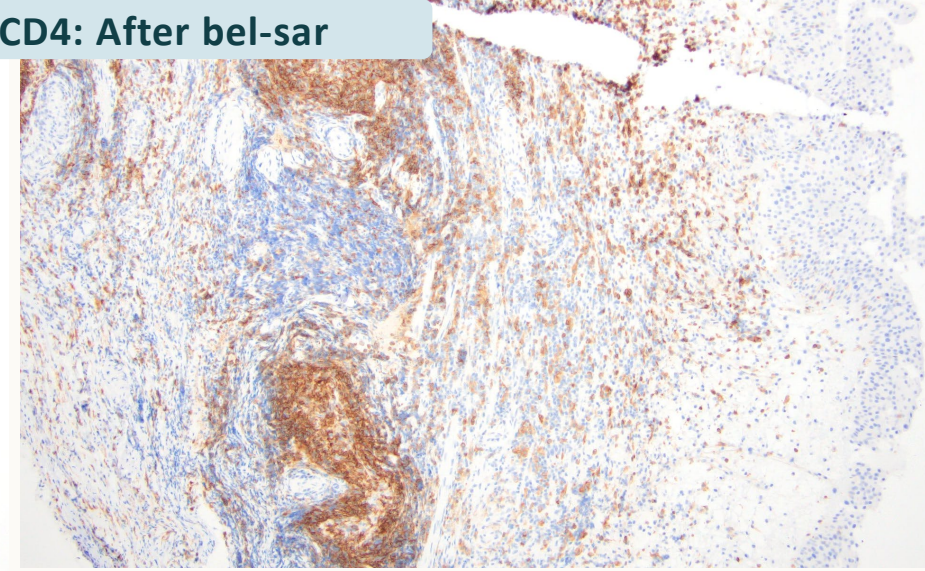
Tumor: Before bel-sar



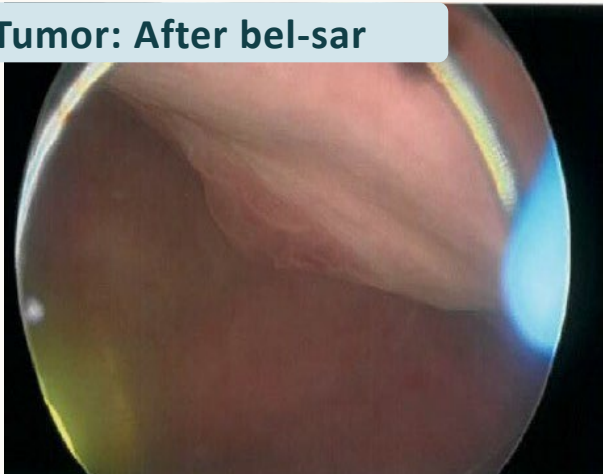
H&E: After bel-sar



CD4: After bel-sar



Tumor: After bel-sar



Lymphoid follicles were observed, suggesting a strong adaptive immune response.

Significant infiltration of CD4+/CD8+ T-cells in both treated and untreated tumors, indicating a **urothelial field effect**.

Mature Tertiary Lymphoid Structures (TLS) in Target (Treated) Lesion:

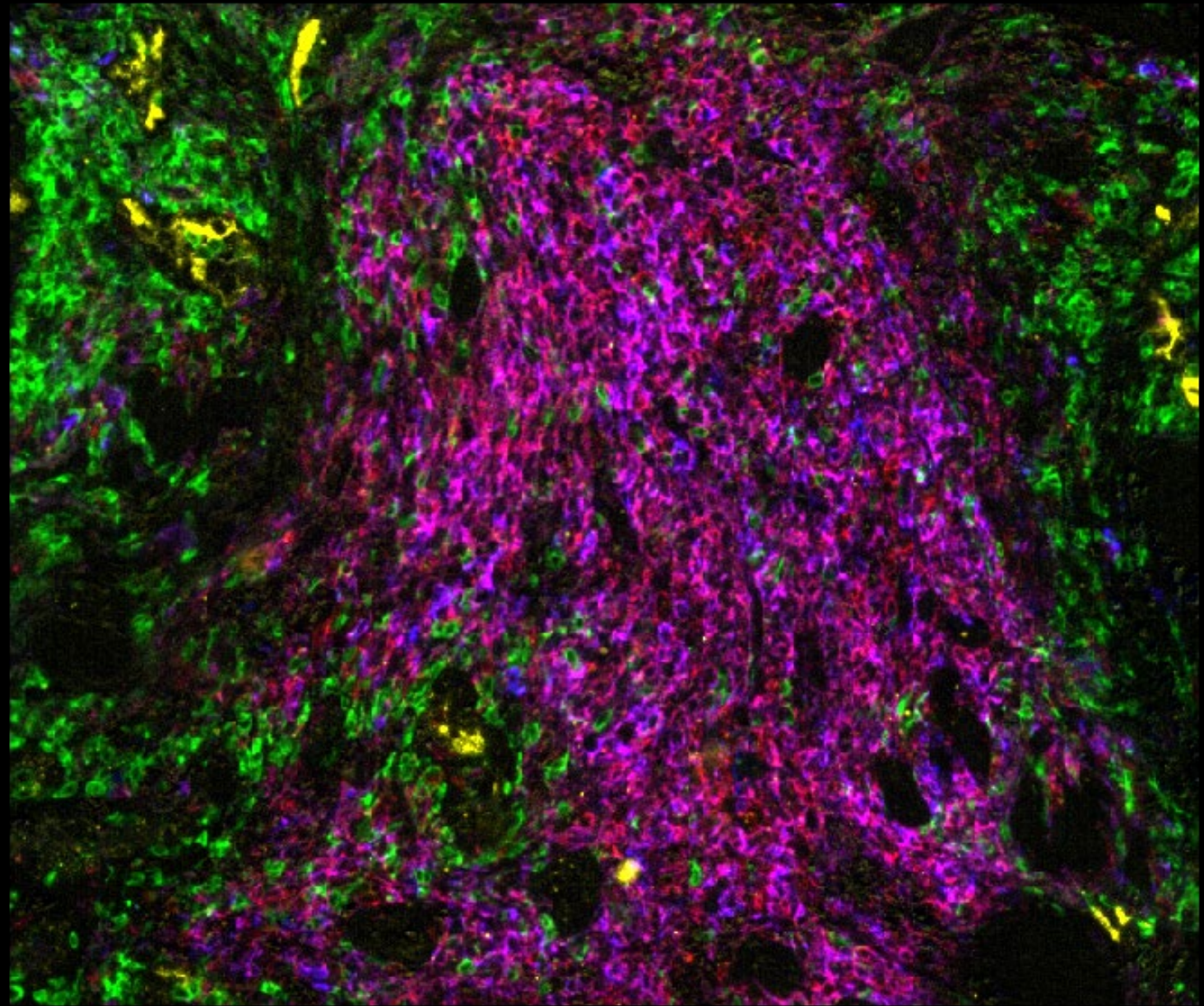
Active Immunosurveillance After Bel-sar Treatment

CD3: T cells

CD20: B cells

CD23: Follicular Dendritic Cells (FDC)
(Found in B cell follicles, only present in mature TLS)

PNAd: Peripheral Node Addressin
(Stains for high endothelial venules, evidence of lymphocyte trafficking from periphery)



Multiplex Immunofluorescence: Patient A3 (Intermediate-Risk NMIBC)

TLS Not Present in Lesion Prior to Treatment

Early Tertiary Lymphoid Structures (TLS) in Distant Non-Target (Non-Treated) Lesion:

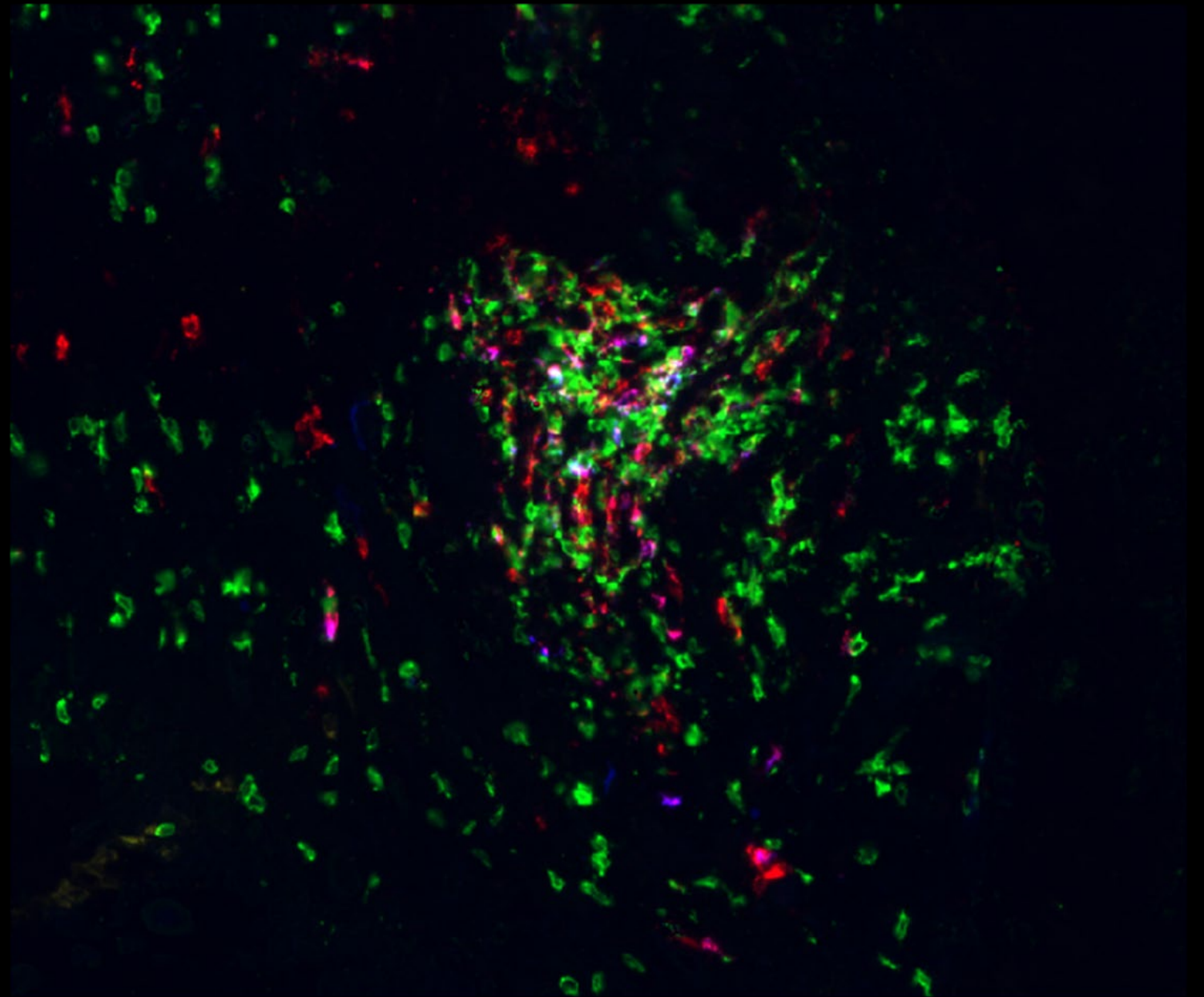
Urothelial Immune Field Effect After Bel-sar Treatment

CD3: T cells

CD20: B cells

CD23: Follicular Dendritic Cells (FDC)
(Found in B cell follicles, only present in mature TLS)

PNAd: Peripheral Node Addressin
(Stains for high endothelial venules, evidence of lymphocyte trafficking from periphery)



**Multiplex Immunofluorescence: Patient A3
(Intermediate-Risk NMIBC)**

Summary and Conclusions Phase 1 Trial

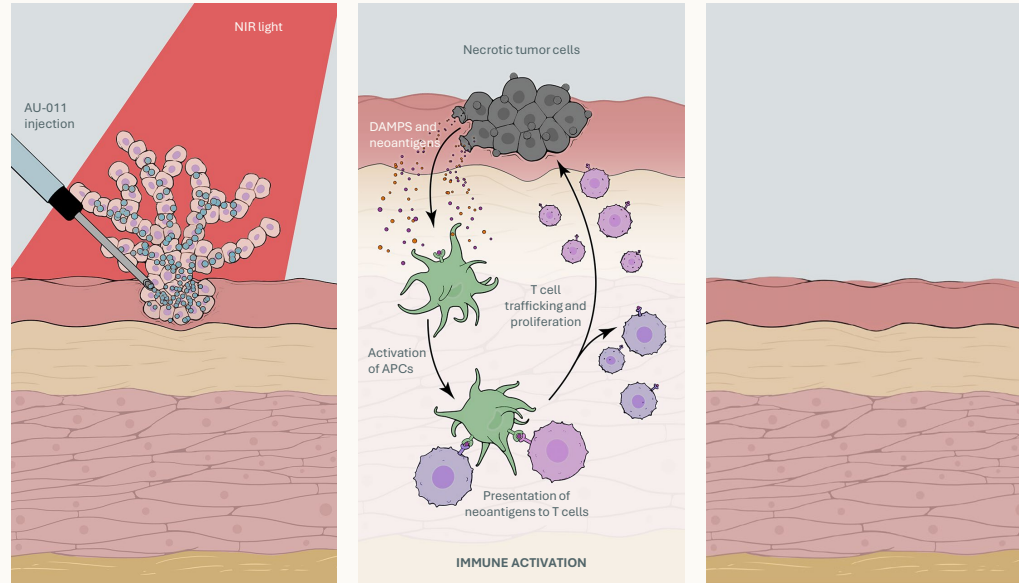
- Dual mechanism of action demonstrated with Virus-like Drug Conjugate:
 - **Tumor cell necrosis with clinical complete response**
 - **Strong local immune response (active immunosurveillance)** with generation of mature TLS
 - Extensive **urothelial field effect** in NMIBC with early TLS visualized in distant, non-treated lesions
- Safety Data:
 - **Only grade 1 drug-related adverse events**
- Biological Activity Data:
 - **IR NMIBC: Clinical Complete Response achieved in 4 out of 5 tumors, and 4 non-target tumors**
 - **HR NMIBC: Tumor shrinkage occurred in 3 out of 5 patients, although tumor cells remained on pathology; one complete response in a target tumor**
- Field Effect:
 - Clinical complete response in both treated and non-treated lesions within 7 to 12 days suggests the potential of AU-011 as a promising upfront immune-ablative treatment.

Future Directions for VDC Development in Bladder Cancer

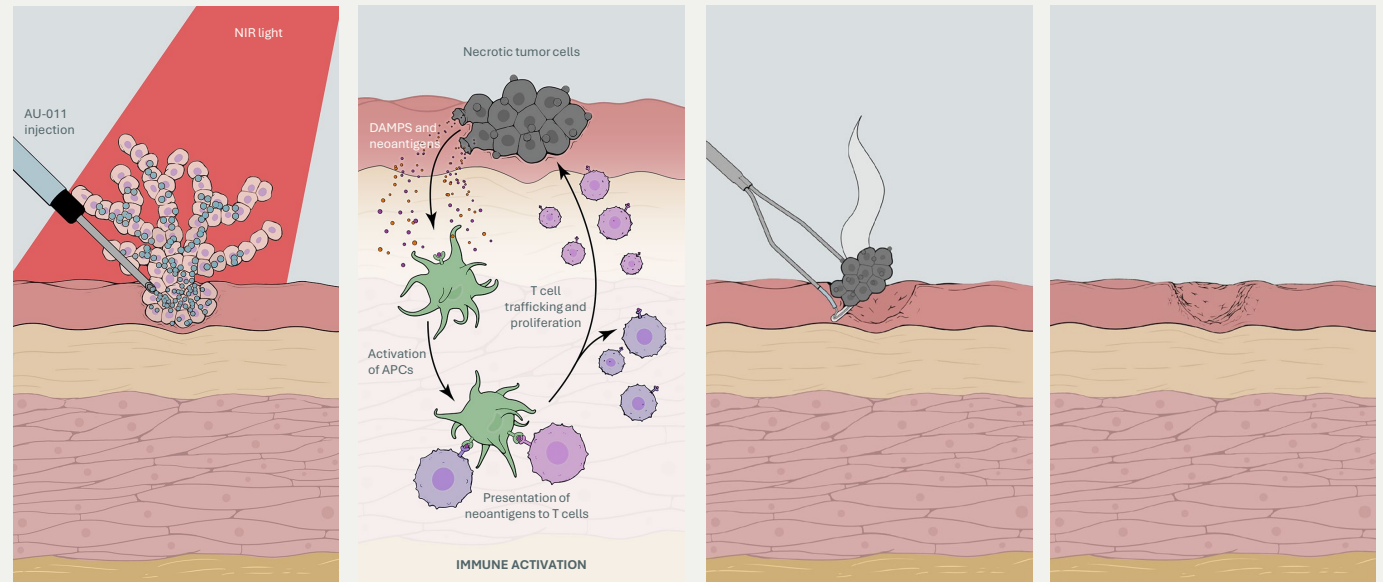
Potential standalone treatment or neoadjuvant/multimodal treatment

Immune-ablative approach could eliminate the need for TURBT, or be used prior to resection to improve treatment outcomes

1
Immune-ablative treatment without TURBT
 (LR/IR NMIBC)



2
Neoadjuvant/multimodal therapy followed by TURBT
 (IR/HR NMIBC)



APC, antigen-presenting cell; AU-011, belzupacap sarotalocan; DAMPs, damage-associated molecular patterns; HR, high-risk; IR, intermediate risk; LR, low-risk; NIR, near-infrared; NMIBC, non-muscle-invasive bladder cancer; TURBT, transurethral resection of bladder tumor.

Virus-like Drug Conjugates (VDC)

**A paradigm shifting
approach for the
treatment of bladder
cancer**

Mechanism

First Insights

Future Directions

Panel Discussion

- Dr. Peter Black, Vancouver (CA)
- Dr. Laura Bukavina, Cleveland (US)
- Dr. Shahrokh Shariat (AUT)
- Dr. Sabine Brookman-May (DE, US), Aura Biosciences, Boston